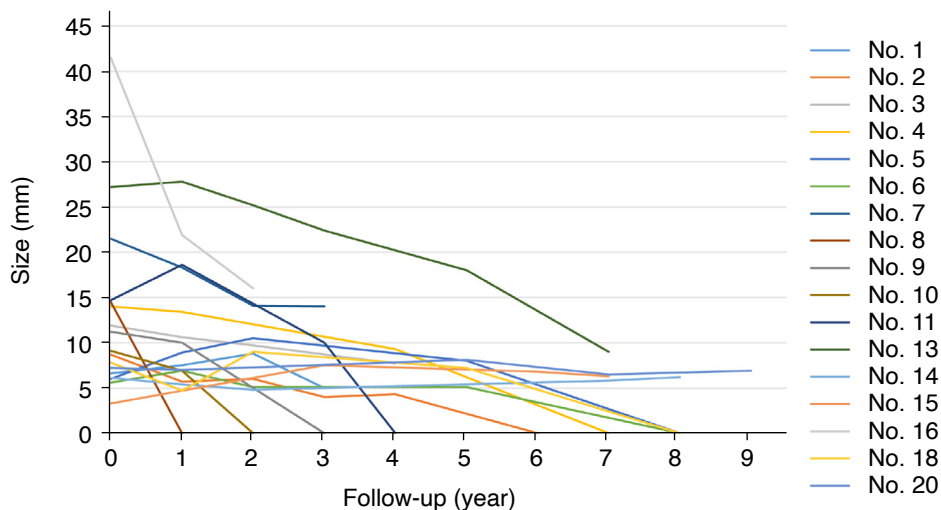


Supplementary Method 1. Patient selection.

Patients with pathologies suspected to be suture granulomas were included in this study. Four patients exhibited suture materials with surrounding foreign body granuloma or foreign body reaction, pathologically confirming definite suture granuloma. Additionally, 14 patients showed foreign body granuloma or foreign body reaction but lacked definite suture materials in the specimen. However, the lesions were clinically diagnosed as suture granuloma when the patients met criteria as described below: (1) Surgeons used suture materials, not Harmonic scalpel, for vessel ligation during thyroidectomy; (2) Patients had no clinical history of potential causes for foreign body granuloma other than suture granuloma in the neck—such as tattoo, cosmetic filler, trauma, etc.; (3) A pathologist reviewed specimen and confirmed likelihood of a diagnosis for suture granuloma

Benign lesions other than suture granuloma (n=54), indeterminate lesions (n=2), and malignant lesions with a non-thyroid origin (n=2) were excluded. Benign lesions other than suture granuloma included benign postoperative lesions—stromal fibrosis, granulation tissue, and fibroadipose tissue (n=42), remnant thyroid tissue (n=7), and parathyroid lesions (n=5). Indeterminate lesions included atypia of undetermined significance with architectural atypia and equivocal tumor capsule (n=1), and a few atypical cells of undetermined significance (n=1). Malignant lesions with a non-thyroid origin included squamous cell carcinoma from hypopharyngeal cancer (n=1) and laryngeal cancer (n=1).



Supplementary Fig. 1. Recurrent tumor misdiagnosed as suture granuloma on ultrasonography.