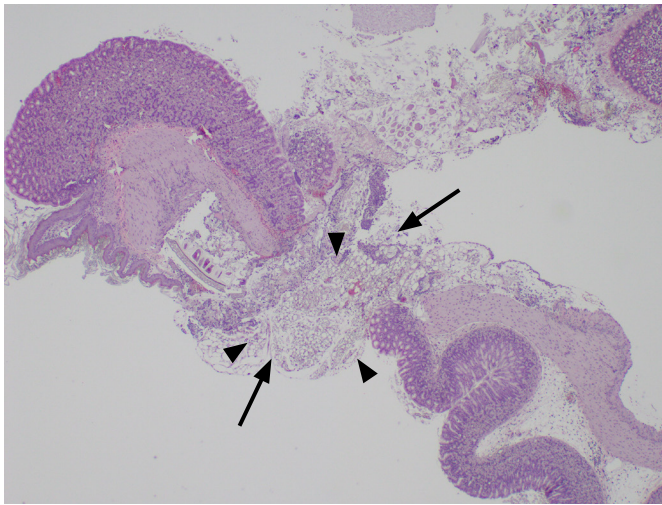
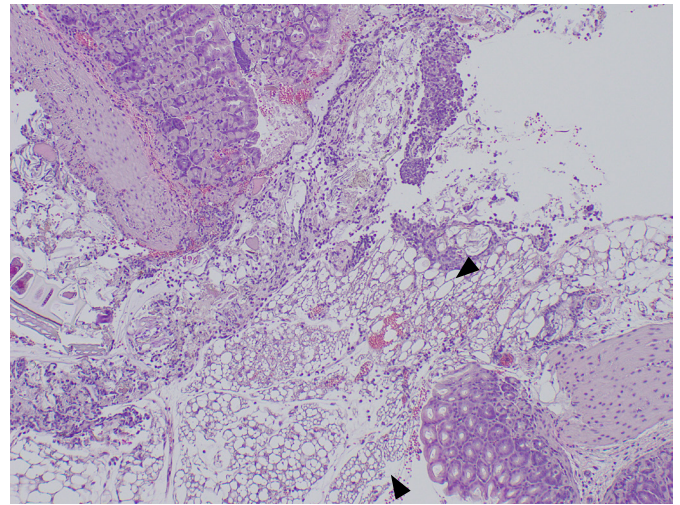


Supplementary Fig. 1. Schema of experimental design. All mice received contrast enhanced ultrasonography (CEUS) three times. First, CEUS with intraperitoneal Sonazoid injection was performed followed by preoperative CEUS with oral Sonazoid administration (preoperative CEUS) and finally CEUS with oral Sonazoid administration after gastric perforation has been surgically generated (post-operative CEUS). Each CEUS was performed with an interval of at least 1 week.



A



B

Supplementary Fig. 2. Microscopic image of stomach specimen demonstrating the perforation site (arrows) at the gastric wall with acute suppurative necrotizing exudates (arrowheads) and submucosal edema (hematoxylin and eosin staining; **A**, $\times 40$; **B**, $\times 100$).